

# Short-pulse carbon dioxide laser resurfacing of the neck

Daniel S. Behroozan, BS, Mary M. Christian, MD, and Ronald L. Moy, MD  
*Los Angeles, California*

**Background:** Carbon dioxide (CO<sub>2</sub>) laser resurfacing of the face has become an increasingly popular procedure. However, laser resurfacing of the neck has been largely avoided because of fears of scarring or pigmentation changes.

**Objective:** Our purpose was to evaluate the efficacy of treatment and incidence of complications after short-pulse CO<sub>2</sub> laser resurfacing of the neck.

**Methods:** A total of 308 patients received concomitant face and neck CO<sub>2</sub> laser resurfacing. A 90- $\mu$ s pulse duration CO<sub>2</sub> laser without a scanner was used in all cases for 2 passes on the neck (10.6- $\mu$ m wavelength, 500-mJ pulse energy, 90- $\mu$ s duration, 3-mm spot size) and a continuous CO<sub>2</sub> laser with a computer-generated scanner (396- $\mu$ s dwell time, 18 W) was used for 3 passes over the face except for the perioral area, which received 4 passes. The incidence of scarring or permanent pigmentation changes was determined. Forty patients who had been treated at least 6 months but no longer than 18 months earlier were randomly surveyed by phone to assess the degree of improvement.

**Results:** Of the 308 patients treated, there were no cases of scarring or permanent pigmentation changes. Surveyed patients reported a 39% improvement in rhytides and tightening on the neck.

**Conclusion:** Resurfacing of the neck can be performed safely in conjunction with resurfacing of the face. Patients may be offered improvement in the neck with little chance of scarring or permanent pigmentary changes when resurfacing on the neck is performed by means of a short-pulse duration laser for a limited number of passes instead of the more aggressive laser parameters previously used such as continuous long-pulse duration treatments. (*J Am Acad Dermatol* 2000;43:72-6.)

Laser resurfacing of the face has become increasingly popular. Most surgeons currently performing laser resurfacing tend to avoid the neck because of fears of scarring or pigmentation changes. Prominent laser surgeons have advocated avoiding resurfacing of the neck because of scarring in 30% of their reported cases.<sup>1</sup> Other studies have shown some benefits and complications of laser neck resurfacing.<sup>2,3</sup> This article presents a study of patients over a period of 2 years who underwent simultaneous full face and neck resurfacing by means of a 90- $\mu$ s pulse duration carbon dioxide (CO<sub>2</sub>) laser on the neck. The purpose of this article is to evaluate the efficacy of treatment and incidence of complications after short-pulse CO<sub>2</sub> laser neck resurfacing.

## MATERIAL AND METHODS

A total of 308 patients received concomitant face and neck CO<sub>2</sub> laser resurfacing and were included in this study. All patients had Fitzpatrick skin types I, II, or III. Patients received prophylactic oral valacyclovir, 500 mg twice daily, for a period of 10 days, starting 1 day before surgery. Local intravenous sedation or general anesthesia was provided by an anesthesiologist. The 90- $\mu$ s pulse duration CO<sub>2</sub> laser without a scanner was used in all cases on the neck (10.6- $\mu$ m wavelength, 500-mJ pulse energy, 90- $\mu$ s duration, 3-mm spot size; TruePulse, Albuquerque, NM). Laser pulses were placed adjacent to each other without overlap, and 2 passes were performed over the entire neck. A saline wipe was performed between passes but not after the second pass. Each pass of resurfacing over the neck took approximately 10 minutes to complete. A continuous-wave CO<sub>2</sub> laser (Sharplan, Norwood, Mass) with a computer-generated scanner (396- $\mu$ s dwell time, 18 W) was used for 3 passes over the face, except for the perioral area, which received 4 passes. After the procedure, patients were ban-

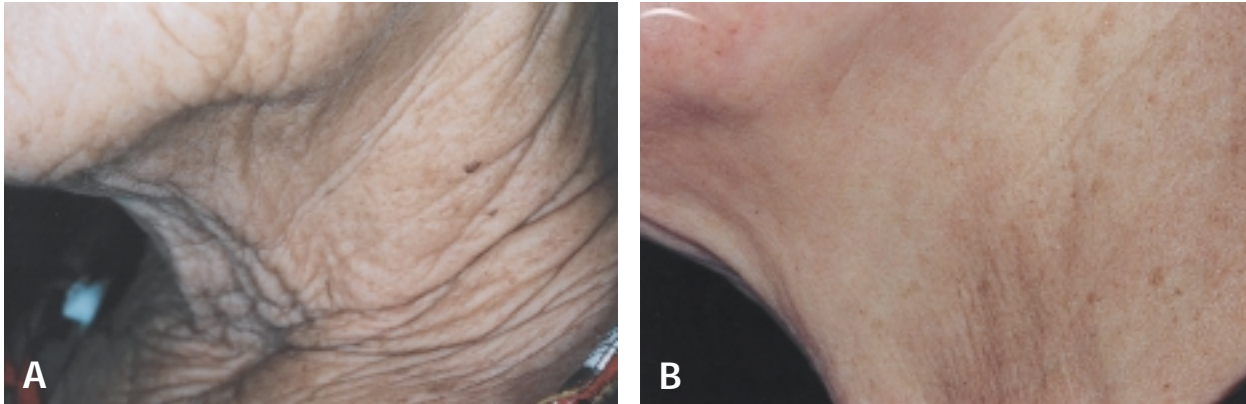
---

From the University of California, Los Angeles, and West Los Angeles Veterans Affairs Medical Center.

Reprint requests: Ronald L. Moy, MD, 100 UCLA Medical Plaza, Suite 590, Los Angeles, CA 90024-6933.

16/1/104795

doi:10.1067/mjd.2000.104795



**Fig 1.** Photographs of neck (A) before and (B) 3 months after treatment in a patient who underwent 2 passes of laser resurfacing by means of a 90- $\mu$ s short-pulse duration CO<sub>2</sub> laser.

daged with Flexzan occlusive dressing (Bertek Pharmaceuticals, Inc, Morgantown, WVa) on the face and neck without saline wiping before bandage placement, and prophylactic antibiotic therapy with cephalexin, 500 mg twice daily, was initiated and continued for 10 days. Bandages were removed on the third day after the procedure, and patients were encouraged to take showers and to apply petroleum jelly regularly to face and neck wounds. Patients were further followed at 1 week, 1 month, 3 months, 6 months, 1 year, and then as needed to monitor the progression of healing. Photographs were taken before the procedure and at periodic office visits after the procedure to document results.

Forty patients (average age, 58 years; age range, 37 to 74 years) who received laser resurfacing to both the neck and face at least 6 months but no longer than 18 months before were randomly selected by computer. These patients were then surveyed by the first author by telephone to assess the degree of improvement patients thought they had as a result of the procedure. A nonparametric statistical sign test analysis was performed to assess the significance of these findings.

## RESULTS

A total of 308 patients underwent laser resurfacing of the neck. Of these, there were no cases of scarring or permanent pigmentation changes. A few patients had temporary hyperpigmentation on the neck depending on the darkness of the skin. Hyperpigmentation responded to hydroquinone 4% cream applied twice daily. Of the 40 patients surveyed by phone, patients noticed a significant improvement from baseline with a 67% improvement in rhytides and tightening of skin in the face (standard error of the mean [SEM] = 3.41) and a

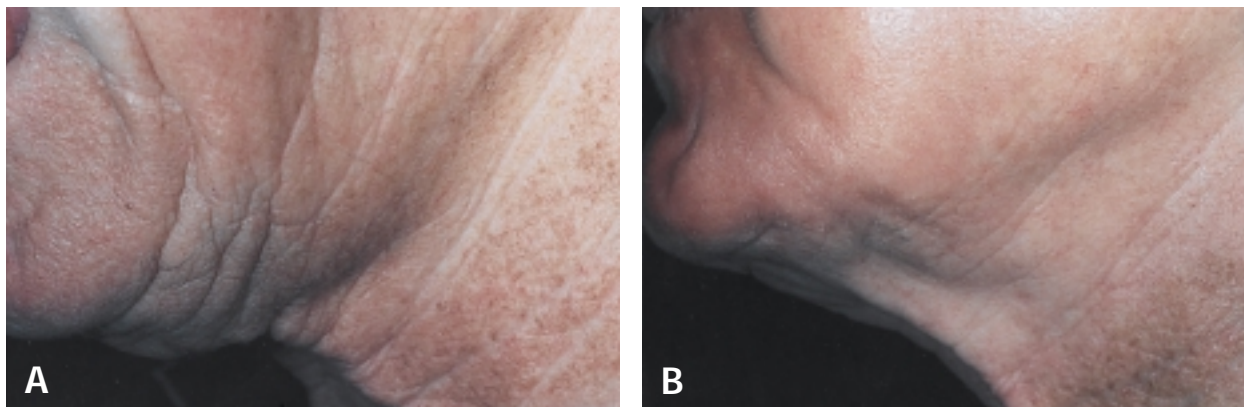
**Table I.** Self-assessment of percent improvement in rhytides and tightening of skin after CO<sub>2</sub> laser resurfacing\*

Percent improvement	Face	Neck
0	0	6
1-19	2	4
20-39	1	8
40-59	8	12
60-79	15	8
80-100	14	2
Average improvement	67%	39%

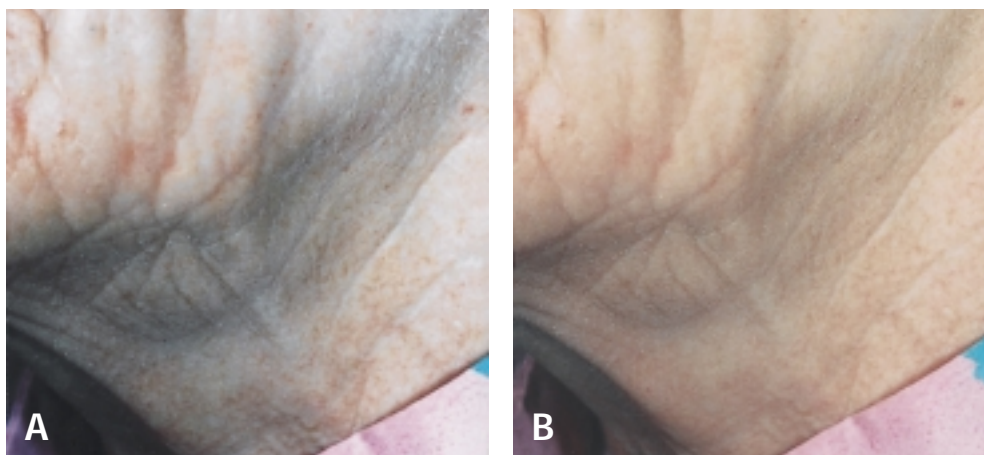
39% improvement in the neck (SEM = 4.40) (Table I). Of patients surveyed, 85% were pleased with the final results of their laser treatment on the neck despite the initial erythema observed; 15% thought they had no improvement in neck rhytides or skin tightness after the resurfacing procedure. The results of a nonparametric statistical sign test analysis performed to assess the significance of these findings showed that there was a significant difference between the median improvement in the face and the neck with the face showing more improvement ( $P < .01$ ). Figs 1-3 show examples of neck skin change as a result of resurfacing.

## DISCUSSION

There is a paucity of studies in the literature outlining the healing response of neck skin after resurfacing procedures. Although neck skin has always been considered a more dangerous area to treat with cosmetic procedures because of a higher likelihood of scarring, the chemical peel literature suggests that there have not been enough cases or adequate evi-



**Fig 2.** Photographs of neck (A) before and (B) 2 months after treatment in a patient who underwent 2 passes of laser resurfacing by means of a 90- $\mu$ s short-pulse duration CO<sub>2</sub> laser.



**Fig 3.** Photographs of neck (A) before and (B) 13 months after treatment in a patient who underwent 2 passes of laser resurfacing by means of a 90- $\mu$ s short-pulse duration CO<sub>2</sub> laser.

dence to detail the exact risk of procedures used to resurface the skin of the neck.<sup>4</sup> In the limited studies that have reported scarring or pigmentation changes after procedures involving the neck, the pathophysiology of the complications has not been completely elucidated and remains theoretical. Some have suggested that these complications may be because of the thinner nature of the neck dermis, which on average is approximately 140  $\mu$ m, whereas the thickness of areas such as the mental region and forehead have been approximated at 1375 and 970  $\mu$ m, respectively.<sup>5</sup> In addition, others have attributed the risks of complications not only to the thinner nature of cervical skin, but also to the sparsity of pilosebaceous units in that area, which have long been hypothesized to be the source of re-epithelialization of neck skin.<sup>2,3,6,7</sup>

This study used a 90- $\mu$ s pulsed CO<sub>2</sub> laser on the neck as described above. Based on the parameters of the laser used in this study, the depth of ablation for facial skin has been estimated to be approximately 100  $\mu$ m for the first pass and 50  $\mu$ m for the second.<sup>8</sup> Although it has been generally accepted that the CO<sub>2</sub> laser is effective in tightening skin and improving rhytides, the mechanism by which it does so remains unclear. However, some have indicated that within several weeks after the procedure there is new ingrowth of collagen fibers in the area of ablation with reorganization of skin.<sup>9-12</sup> In addition, it has been estimated that resurfacing with the 90- $\mu$ s short-pulse laser results in a mean 10% to 20% linear contraction as compared with baseline, and this may be another associated cause of the benefits seen in patients included in this report.<sup>13</sup>

The 308 patients who underwent laser neck resurfacing and were included in this study were retrospectively evaluated for the efficacy of treatment and incidence of complications. There were no cases of scarring or permanent pigmentation changes. Patients were generally satisfied with the results obtained, and there was a visible decrease in rhytides with tightening of skin averaging a 39% improvement on the neck and 67% improvement on the face based on a random survey of 40 patients who underwent this procedure. Thus preliminary data suggest that this treatment modality may have fewer complications after the procedure than previously used cosmetic techniques for neck skin, such as chemical peels, dermabrasion, or neck lifts, all of which have reported complications. Complications of chemical peeling in the past have included pigmentary changes, excessive erythema, hypertrophic scarring, and atrophy.<sup>14</sup> Similarly, dermabrasion has been plagued with similar adverse results, most commonly milia, hypertrophic scarring, pigmentary change contact dermatitis, granulomas, skin necrosis, and infection.<sup>6</sup>

It should be noted that previous reports of laser resurfacing of the neck have shown complications including thickening of cervical skin folds, onset of whitish streaks on the neck, and increases in telangiectases<sup>2,3</sup>; the patients in our study experienced none of these complications. Moreover, it has been argued that laser resurfacing of the neck should not be performed at all because of reported complications including hypertrophic scarring, visible streaks of fibrous bands, and stretching of the cervical skin after laser treatment of the neck.<sup>1</sup> This same group reported 3 cases of scarring among 10 patients treated with the 950- $\mu$ s pulsed CO<sub>2</sub> laser on the neck. In contrast, no cases of permanent scarring were observed in the 308 patients reported in this study, and this may largely be attributed to the short-pulse duration laser (90  $\mu$ s) used on the neck in this study as compared with more aggressive long-pulse duration lasers (950  $\mu$ s) used in the above report. Other reports have shown the benefits of neck dermis and fascia laser resurfacing when used in combination with liposculpture.<sup>15</sup> Limited studies using the erbium:YAG laser on the neck have also been promising<sup>16</sup> but had a limited sample size of 10 patients and only a 6-month follow-up period, making significant conclusions difficult. It is the authors' view that the results of this study suggest that the complications of neck resurfacing can be avoided when short-pulse duration laser parameters are used on the neck as compared with the face, which apparently is better able to withstand more aggressive treatment with longer pulse dura-

tion lasers. The use of long-pulse duration lasers or overly aggressive treatment of the neck with short-pulse duration CO<sub>2</sub> lasers should be avoided because of previously described complications as discussed above.

The improvement calculated on the face in this study of 67% agrees with other studies that have calculated mean improvement percentages for the face such as Shim et al,<sup>10</sup> who observed an average 70% improvement in rhytides. On the other hand, Alster and Garg<sup>17</sup> found a 90% improvement in the face, whereas Fitzpatrick et al<sup>18</sup> showed only a 46% to 48% improvement on the face. It should be noted that there has been no uniform scale among studies in the determination of clinical improvement of rhytides after CO<sub>2</sub> laser resurfacing and that the assessment of improvement is definitely a subjective one. Thus it is difficult to make accurate comparisons between different studies on the face. Moreover, the results calculated in this study are based on the patients' own telephone assessment of improvement and not on an objective clinical analysis by a physician, and as such, this limitation makes it possible for conflicting variables such as appointment availability or staff courtesy to have affected patients' responses. Finally, to the authors' knowledge, there have been no previous studies that have attempted to assess the degree of improvement on the neck compared with the face.

Neck laser resurfacing provides several advantages over more traditional therapies. The physician has greater control over the depth of tissue destruction allowing for a faster recovery time and, according to the data presented, a lower incidence of scarring and other permanent pigmentary changes than chemical peeling or dermabrasion. In addition, CO<sub>2</sub> laser resurfacing of the neck when used in conjunction with resurfacing of the full face provides a more homogeneous change in color and texture, avoiding the line of demarcation often observed at the jaw of patients who receive a procedure to either site alone. The fact that the magnitude of improvement perceived by patients in the face (67%) was greater than that in the neck (39%) may be related to the more conservative laser parameters used to treat the neck and is substantiated by the fact that 6 of the 40 patients surveyed indicated no improvement (0%) in the neck area, whereas no patients did so for the face (Table I). It should also be noted that most patients who present for laser resurfacing do so for facial rhytides and not for improvement of the skin of the neck; thus it is possible that the differences seen between the median improvements in the face and the neck in this study may have been because patients generally pay more attention to the

improvement of facial skin than that of the neck. Nevertheless, the 40 patients surveyed in this study did report a mean 39% improvement in rhytides and tightening of the skin and, overall, were pleased with the end result. Furthermore, none of the 308 patients in this study experienced any scarring or permanent pigmentary changes when resurfacing of the neck was performed by means of a short-pulse duration laser. Thus, for patients who either do not want to undergo a surgical lift of the neck or are ineligible for surgical treatment because of medical contraindications, laser resurfacing of the neck provides a safe alternative that can show beneficial results.

Although laser surgeons have traditionally feared treating the neck because of the thinner nature of cervical skin and the associated risk of scarring, the results of this study suggest that laser resurfacing of the neck can be an effective procedure with limited morbidity when resurfacing is performed by means of a short-pulse duration laser. The 40 patients surveyed in this study reported a significant improvement from baseline in rhytides and tightening of cervical skin; none of these patients experienced scarring or permanent pigmentary changes. Although not all patients treated with laser resurfacing show dramatic responses, there can be a marked improvement for some patients who suffer from photodamaged skin and wrinkles coupled with a tightening of the cervical skin. Further studies are needed to define the optimal parameters for CO<sub>2</sub> laser neck resurfacing in addition to elucidating the factors that have led to undesired results such as scarring seen in previous studies. Our results show that the experienced laser surgeon may use neck resurfacing in conjunction with face resurfacing, offering patients a more homogeneous end result with little chance of scarring or permanent pigmentary changes in the neck.

#### REFERENCES

1. Fitzpatrick RE, Goldman MP. Resurfacing of photodamage of the neck using the Ultrapulse CO<sub>2</sub> laser [abstract]. *Lasers Surg Med* 1997;Suppl 9:33.
2. Fanous N, Prinja N, Sawaf M. Laser resurfacing of the neck: a review of 48 cases. *Aesthet Plast Surg* 1998;22:173-9.
3. Rosenberg GJ. Full face and neck laser skin resurfacing. *Plast Reconstr Surg* 1997;10:1846-54.
4. Brody HJ. *Chemical peeling and resurfacing*. St Louis: Mosby; 1997.
5. Gonzalez-Ulloa M, Castillo A, Stevens E, Fuertes GA, Leonelli F, Ubaldo F. Preliminary study of the total restoration of the facial skin. *Plast Reconstr Surg* 1954;13:151-61.
6. Rossiter JL. Dermabrasion: clinical uses in otolaryngology. *J Otolaryngol* 1994;23:347-53.
7. Salasche SJ, Bernstein G, Senkarik M. *Surgical anatomy of the skin*. Norwalk (CT): Appleton & Lange; 1988.
8. Moy RL, Bucalo BD, Lee MH, Wider JM, Chlaet MD, Ostad A, et al. Skin resurfacing of facial rhytides and scars with the 90 microsecond short pulse CO<sub>2</sub> laser. *Dermatol Surg* 1998;24:1390-6.
9. Ratner D, Viron A, Puvion-Dutilleul F, Puvion E. Pilot ultrastructural evaluation of human preauricular skin before and after high energy pulsed carbon dioxide laser treatment. *Arch Dermatol* 1998;134:582-7.
10. Shim E, Tse Y, Velazquez E, Kamino H, Levine V, Ashinoff R. Short-pulse carbon dioxide laser resurfacing in the treatment of rhytides and scars. *Dermatol Surg* 1998;24:113-7.
11. Stuzin JM, Baker TJ, Baker TM, Kligman AM. Histologic effects of the high energy pulsed carbon dioxide laser on photoaged facial skin. *Plast Reconstr Surg* 1997;99:2036-50.
12. David LM, Lask GP, Glassberg E. Laser abrasion for cosmetic and medical treatment of facial actinic damage. *Cutis* 1989;43:583-4.
13. Bucalo BD, Moy RL. Quantitative comparison of inflammatory infiltrate and linear contraction in human skin treated with 90 microsecond pulsed and 900 microsecond dwell time carbon dioxide lasers. *Dermatol Surg* 1998;24:1314-6.
14. Resnik SS, Resnik BI. Complications of chemical peeling. *Dermatol Clin* 1995;13:309-12.
15. Cook WR. Laser neck and jowl liposculpture including platysma laser resurfacing, dermal laser resurfacing, and vaporization of subcutaneous fat. *Dermatol Surg* 1997;23:1143-8.
16. Goldberg DJ, Meine JG. Treatment of photoaged neck skin with the pulsed erbium:YAG laser. *Dermatol Surg* 1998;24:619-21.
17. Alster TS, Garg S. Treatment of facial rhytides with a high-energy pulsed carbon dioxide laser. *Plast Reconstr Surg* 1996;98:791-4.
18. Fitzpatrick RE, Goldman MP, Satur NM, Tope WD. Pulsed carbon dioxide laser resurfacing of photoaged facial skin. *Arch Dermatol* 1996;132:395-402.